

Constrictive Pericarditis and Cardiac Tamponade Due to Tuberculosis as Presentation of Human Immunodeficiency Virus/Syndrome of Acquired Immunodeficiency: Case Report

Mariana Rada-Rada¹ , Ana Quintana-Londoño¹ , Sergio Latorre-Alfonso² , José Polo-Nieto³, 
Sebastián Cruz-Rivera⁴ 

Abstract

We report a case of constrictive pericarditis due to extrapulmonary tuberculosis associated with Human Immunodeficiency Virus, complicated by cardiac tamponade that required surgical intervention in a drug user patient. The importance of early diagnosis and management is widely highlighted.

Keywords: extrapulmonary tuberculosis; constrictive pericarditis; cardiac tamponade; immunosuppression; human immunodeficiency virus.

¹ Fundación Universitaria de Ciencias de la Salud (Bogotá, Colombia).

² Internal Medicine Department, Hospital Universitario Infantil de San José-Fundación Universitaria de Ciencias de la Salud (Bogotá, Colombia).

³ Pathology Department, Hospital Universitario Infantil de San José-Fundación Universitaria de Ciencias de la Salud (Bogotá, Colombia).

⁴ Emergency Department, Hospital de San José, Fundación Universitaria de Ciencias de la Salud (Bogotá, Colombia).

Corresponding author: Mariana Rada Rada. Email: mrada@uniboyaca.edu.co

How to cite this article:

Rada-Rada M, Quintana-Londoño A, Latorre-Alfonso S, Polo-Nieto J, Cruz-Rivera S. Pericarditis constrictiva y taponamiento cardíaco por tuberculosis como presentación de virus de inmunodeficiencia humana/síndrome de inmunodeficiencia adquirida: presentación de caso. Rev Investig Salud Univ Boyacá. 2023;10(1):165-177. <https://doi.org/10.24267/23897325.898>

Pericarditis constrictiva y taponamiento cardíaco por tuberculosis como presentación de virus de inmunodeficiencia humana/síndrome de inmunodeficiencia adquirida: presentación de caso

Resumen

El artículo presenta un caso de pericarditis constrictiva secundaria a tuberculosis extrapulmonar en un paciente con prueba positiva para virus de inmunodeficiencia humana (VIH) consumidor de sustancias psicoactivas, quien durante la hospitalización desarrolló un taponamiento cardíaco con requerimiento de intervención quirúrgica. Se plantea la discusión de la importancia de cada una de las pruebas solicitadas y el manejo adecuado en pacientes con dichas patologías.

Palabras clave: tuberculosis extrapulmonar; pericarditis constrictiva; taponamiento cardíaco; inmunosupresión; virus de inmunodeficiencia humana.

Pericardite constrictiva e tamponamento cardíaco devido à tuberculose com uma apresentação do vírus da imunodeficiência adquirida: relato de caso

Resumo

O artigo apresenta um caso de pericardite constrictiva secundária à tuberculose extrapulmonar em paciente com teste positiva para vírus da imunodeficiência humana (HIV) e usuário de substâncias psicoativas que, durante a internação, desenvolveu tamponamento cardíaco com necessidade de intervenção cirúrgica. Discute-se a importância de cada um dos exames solicitados e o manejo adequado de pacientes com essas patologias.

Palavras-chave: tuberculose extrapulmonar; pericardite constrictiva; tamponamento cardíaco; imunossupressão; vírus da imunodeficiência humana.

Introduction

Mycobacterium tuberculosis can reach the pericardium through the mediastinal, paratracheal, and peribronchial lymph nodes, directly from the lung to the pleura or via the hematogenous route. This last route of dissemination occurs mainly in immunocompromised patients, given the greater replication and load of the bacillus (1), which enables the development of constrictive pericarditis, a clinical entity in which the formation of granulation tissue in the pericardium results in a loss of pericardial elasticity and a restriction in the ventricular filling. It manifests with signs and symptoms of congestive heart failure, preserved left ventricular ejection fraction, and complications such as cardiac tamponade (2).

Worldwide, the leading cause of constrictive pericarditis is tuberculosis (TB), with a pericardial effusion occurring in half of infected patients, even when they receive anti-tuberculosis treatment (3). In developed countries, acute pericarditis is idiopathic in origin or develops in a post-infectious stage after a viral infection. It may also happen as a complication of any cardiac surgery, associated with mediastinal radiotherapy, and has been related to connective tissue diseases (4).

With the COVID-19 pandemic, there was a multi-year regression in the provision of essential services. The most obvious impact is a significant

global drop in people newly diagnosed and reported with TB. In Colombia, according to the Tuberculosis Surveillance Behavior report, the incidence rate of TB in all forms went from 27.6 per 100,000 inhabitants in 2019 to 25.9 per 100,000 in 2021. Regarding the location of TB, it occurred in its extrapulmonary form in 17.7%, with the most frequent being pleural, meningeal, lymph node, and peritoneal. Besides, 12.8% of people with TB had coinfection with HIV (5). In the case described herein, the clinical, pathological, and imaging findings of a young patient with pericardial TB as a manifestation of HIV/AIDS infection are described. Given the global context and the possibility of increased incidence, timely diagnosis and treatment are necessary, in addition to elucidating the importance of each test requested and appropriate management in patients with such pathologies.

Case presentation

We present the case of a homeless 28-year-old man, born and resident of Bogotá (Colombia), with an extensive history of consuming psychoactive substances, mainly cocaine-based paste and tetrahydrocannabinol. He was admitted to the university hospital with nine days of evolution clinical symptoms: cough with whitish and hemoptoic expectoration, throbbing holocranial headache, multiple diarrheal stools without mucus or blood, asthenia, and adynamia. During the

physical examination, he had a temperature of 38.6°C, a heart rate of 137 beats per minute, a respiratory rate of 22 breaths per minute, oxygen saturation of 81 % on ambient air, with intercostal retractions, expiratory wheezing, and crackle at the left lung base. In the rest of the physical examination, there were no further alterations. The values summarized in Table 1 were found in the admission paraclinical studies.

Table 1. Admission paraclinical tests

Study	Results	
Hemogram	White blood cells	8.22-10e3/uL
	Hemoglobin	9.5 g/dl
	Hematocrit	30.4 %
	Medium corpuscular volume	78.2 fL
	Mean corpuscular hemoglobin	24.4
	Platelets	248,000-10e3/uL
D-dimer	>1,600 ng/mL	
Acute phase reactants	Erythrocyte sedimentation rate	25 mm/1 h
	Polymerase chain reaction	129.58 mg/dL
Arterial gases	pH	7.49
	Partial pressure of carbon dioxide	21.4 mmHg
	Partial pressure of oxygen	78.2 mmHg
	Bicarbonate	16.1 mmol/L
	Excess base	4.7 mmol/L
SARS-CoV-2 antigen	Negative	
Serial bacilloscopy	Negative	

Study	Results
HIV antibodies	Positive
CD4	135 cell/mm

HIV: human immunodeficiency virus; CD4: T4 lymphocytes.

The chest x-ray reading on admission showed middle lobe atelectasis, right pleural effusion, and increased cardiac silhouette with a cardiothoracic index >50% (Figure 1). Given these findings and the patient's context, a contrast-enhanced chest angiotomography was performed (Figures 2 and 3), which documented bilateral pleural effusion predominantly on the left, passive atelectasis of the left lower lobe, middle lobe and lingula, and 36 mm-thick pericardial effusion. The patient was taken to a transthoracic echocardiogram with evidence of severe pericardial effusion, separation of the anterior (25 mm) and posterior (21 mm) pericardial sheets, signs of increased intrapericardial pressure, given by biventricular diastolic collapse, a thickened spongiform visceral pericardium, and evidence of highly mobile spiculated images.

Figure 1. Chest x-ray.

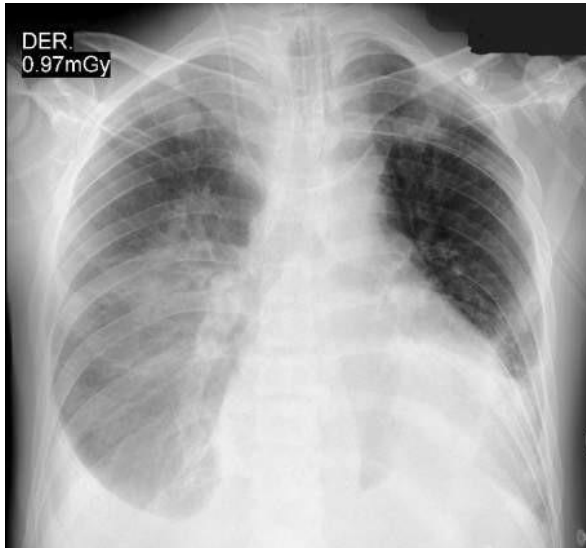

Figure 2. Axial section of the lung window with left pleural effusion of 23 mm interpleural distance.

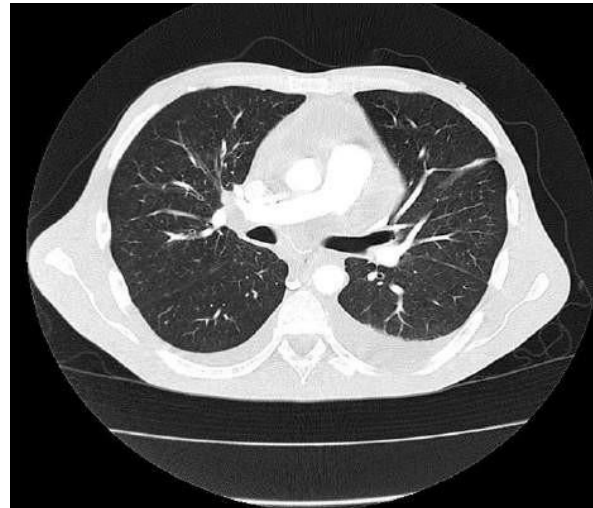
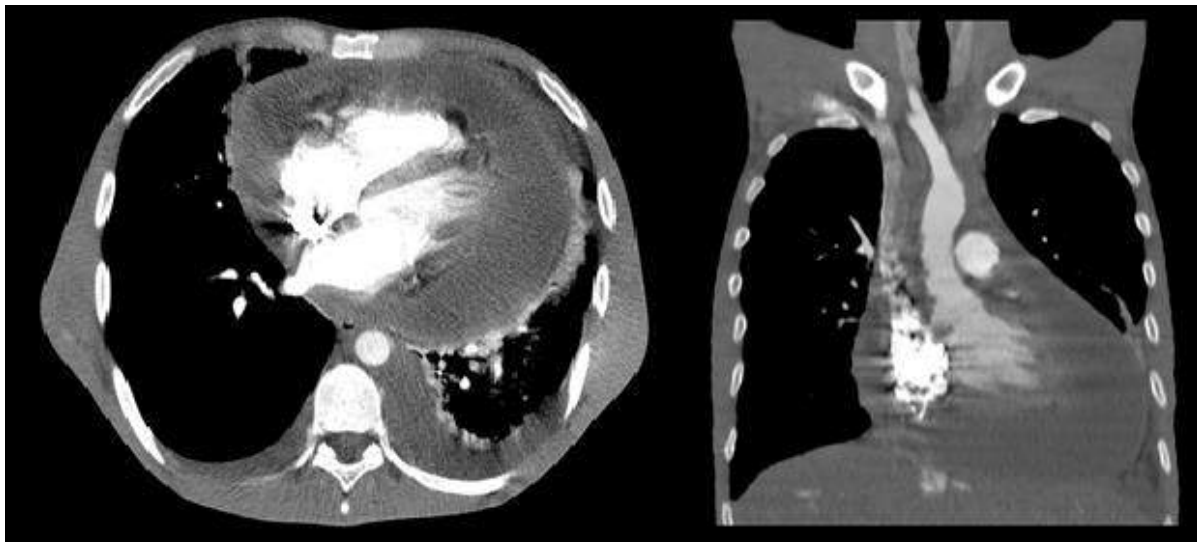


Figure 3. Contrast-enhanced chest tomography in the axial section with coronal reconstruction in the mediastinal window. Cardiac chambers of the usual size. 36 mm-thick pericardial effusion.



Consequently, the patient was taken to ultrasound-guided pericardiocentesis, and subsequent analysis of the pericardial fluid, which documented red, slightly cloudy liquid with 95 % fresh red blood cells, 30 leukocytes per mm³, 18 % neutrophils, 72 % lymphocytes, 9 % monocytes, glucose: 98, proteins: 4.22 g/dL, lactate dehydrogenase: 1,469, albumin: 1.76 g/dL, negative culture, and adenosine deaminase (ADA).

Given the recent diagnosis of HIV with a high suspicion of very low CD4, the ADA value in the pericardial fluid, and the presence of hepatosplenomegaly, antituberculosis treatment was started empirically with the HRZE regimen (rifampicin 150 mg, isoniazid 75 mg, pyrazinamide 400 mg, and ethambutol 275 mg orally). Forty-eight hours after the pericardiocentesis, the patient clinically worsened due to hypotension, feverish peaks, grade III jugular engorgement, paradoxical pulse, and muffled heart sounds. Thus, it was considered that he had cardiac tamponade, and he was taken for a pericardial window with the insertion of a pericardial catheter, in which biopsies were taken in addition to new fluid samples.

Subsequently, the patient was taken to the intensive care unit, given the vasopressor support requirement with norepinephrine, vasopressin, and mechanical ventilation. A polymerase chain reaction (PCR) in the pericardial fluid was positive for *Mycobacterium tuberculosis*. A biopsy of

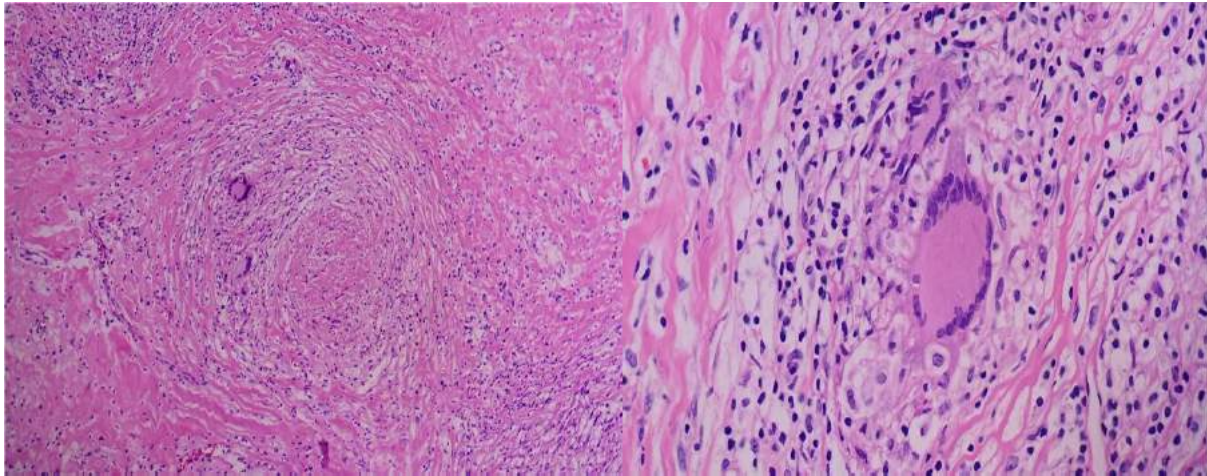
pericardial tissue showed fibrocollagenous tissue with an extensive mixed inflammatory infiltrate of chronic predominance with grouped histiocytes, lymphocytes, and neutrophils that formed granulomas with necrotic centers.

Mature adipose tissue and striated muscle fibers were noticed without atypia or dysplasia, which led to the conclusion that it was a necrotizing granulomatous inflammation. Furthermore, the Ziehl-Neelsen special stain was positive for acid-fast bacilli (*Mycobacterium*), confirming the pericardial TB diagnosis (Figures 4A and 4B). The patient had a good postoperative evolution, with a progressive decrease in vasoactive support and improved oxygenation indices. He was transferred to a room, the pericardial drainage catheter was removed, and given the progress, he was discharged with colchicine, prednisone (for progressive removal), and HRZE.

DISCUSSION

Humans and *Mycobacterium tuberculosis* have coexisted for more than 70,000 years. This mycobacterium accompanied human migrations and possibly expanded during the Neolithic (6). Characterized by being acid-fast, it is transmitted by aerosols of small particles (droplet nuclei) and infects any tissue in a localized or disseminated manner. Although a lung disease, the bacillus can affect any body organ, and often, cardiac

Figure 4. A) Hematoxylin-eosin 10X. A well-formed granuloma of histiocytes, a ring of lymphocytes, fibroblasts, multinucleated giant cells, and central necrosis is shown. **B)** Hematoxylin-eosin 40X: multinucleated giant cell.



involvement occurs, impacting the serous membranes such as the pericardium (1,7). Every day, 4,100 people die from TB, one of the diseases that causes the most deaths globally.

In Latin America, 88% of the cases worldwide have been documented, and Colombia contributes about 6% (8). The most affected individuals are those with HIV/AIDS since they are 18 times more likely to develop active TB than those without infection, especially in patients with AIDS, where pericardial effusion caused by *M. tuberculosis* reaches more than 85% (1). In Colombia, according to the 2021 report, the age group between 24 and 35 years represented 22.8% of total TB cases, with a predominance in males.

It affects homeless people by 3.1%, and even though mortality has decreased by 13%, there is an increase in fatality compared to 2018. Among the cities reporting the most cases of extrapulmonary TB, up to 34%, was Bogotá (9).

Regarding TB/HIV, its case incidence rate during 2020 was 3.2 cases per 100,000 inhabitants. Pericardial TB in Colombia is so rare that in 2020, there was only one case in the Guainía province (9). A study conducted at the Hospital Militar de Colombia reflects that patients with HIV have a higher risk of co-infection with TB, with a higher incidence when they have CD4+ below 200 cells, regardless of viral load. Of the extrapulmonary manifestations, pericardial and

gastrointestinal forms were found to be the most uncommon (10).

For the diagnosis of TB, the clinical symptoms, the laboratory results, and infection and disease factors must be considered, such as poverty, overcrowding, smoking, and HIV/AIDS. In the latter population, a higher risk of progression to active disease and a higher recurrence rate have been described (11). In general, the clinical picture of TB is characterized by classic symptoms (fever, night sweats, weight loss, and some symptoms in other affected organs). In contrast, in extrapulmonary TB, the clinical picture involves symptoms and signs attributable to organic damage and its cardiovascular complications, such as pericarditis and myocarditis, sometimes associated with chronic pericardial effusion, severe thickening of the pericardium, and among its complications, constrictive pericarditis and cardiac tamponade (12).

The diagnostic aids for active TB include the Ziehl-Neelsen stain to detect acid-fast bacilli, which allows a rapid diagnosis, and ADA, which is helpful in cases of extrapulmonary TB and the presence of pleural effusion of possible tuberculous etiology. On Ziehl-Neelsen staining, caseating granulomas are evident in up to 87% of cases, but they may be absent in 50% of HIV patients. A meta-analysis in the Spanish population indicated that a high concentration of pleural ADA > 35-40 U/L is a valuable diagnostic tool; with these

cut-off points, it has a specificity of 93% and a sensitivity of 92%. This allows us to make anti-fibrotic initiation decisions empirically (1,13).

Overall, constrictive pericarditis is a rare complication. Among its causes, we find idiopathic/viral (42-49%), post-cardiac surgery (11-37%), post-radiation therapy (31%), connective tissue disease (3-7%), and bacterial infection in 3-6% (TB and purulent pericarditis). Tuberculous pericarditis (TP) occurs in 1-2% of patients with TB in any of these three forms: effusive (80%), constrictive pericarditis (5%), or mixed (15%) (1,2). Clinically, it can manifest as right rather than left heart failure; in this case, the patient presented with dyspnea, positive fluid wave, and jugular engorgement. In some studies, it has been shown that peripheral edema is absent in up to 25% (14,15).

The diagnostic studies include the electrocardiogram, in which no specific signs exist. Still, it is possible to find changes in the segment or wave and atrial fibrillation or jagged P waves. On chest x-ray, it is possible to observe a widening of the cardiac area in up to 90% of cases; globular image "water bottle"; pleural effusion in 40-60%; pulmonary infiltrates and mediastinal lymph nodes, or pericardial calcifications, which are an important sign of constrictive pericarditis, but are not present in 75% of patients (16). Computed tomography is another tool in which

the thickening of the pericardium (>4 mm; in our case, 25 mm and 21 mm) must be proven. This tool has a sensitivity of up to 80%. Since constrictive pericarditis is a complicated diagnosis to make, it has been shown that cardiovascular magnetic resonance images are instrumental. In cases of PT, the pericardium may appear calcified, unlike post-surgical causes (16,17).

Any cause of pericarditis, especially infectious ones, and effusions with rapid accumulation may result in cardiac tamponade produced by decreased left ventricle filling, reducing stroke volume (18). In some cases, patients present with dyspnea, obstructive cardiogenic shock, Beck's triad (decreased heart sounds, increased jugular venous pressure, and hypotension), reflex tachycardia in 77%, and pulsus paradoxus, most of which were noted in the patient (19). In cardiac tamponade, the electrocardiogram is characterized by sinus tachycardia (42%), low QRS voltage, and electrical alternans. On chest x-ray, increased cardiac silhouette is present in 89%, with an echocardiogram showing positive effusion, septal deviation with inspiration, and diastolic collapse (20).

The final diagnosis is based on the presence of tubercle bacilli in the pericardial fluid or on a histological section, culture, or PCR test (11). In these cases, the effective treatment used is the regimen to treat extrapulmonary TB with the

following medications: rifampicin, isoniazid, pyrazinamide, and ethambutol for at least two months, followed by isoniazid and rifampicin for a total of six months. However, in patients in whom treatment is longer than or equal to nine months, it does not have better results and incurs higher costs. Although 50% of patients progress from effusive to constrictive PT, it has been shown that rifampin reduces the incidence of constrictive PT by up to 40%. Hence, providing adequate antibiotic treatment is the response to anti-tuberculosis therapy, as in patients with HIV infection and those without it. However, it is unclear whether short-term TB treatment is more toxic in patients with HIV than in those without HIV. So, rifampicin induces several drug-metabolizing enzymes and transporters.

Accordingly, the concentrations of several antiretroviral drugs decrease with the administration of rifampin, requiring higher doses of antiretrovirals or changing from rifampicin to rifabutin, as it is a weak inducer (11,14). Corticosteroids may be helpful in patients with tuberculous meningitis, tuberculous pericarditis, or miliary TB with refractory hypoxemia.

It has been shown that prednisolone as an adjuvant decreases the incidence of constrictive PT by 46%, independent of the patient's serological status and hospitalization. However, it should be avoided in individuals with HIV due to the increased risk of malignancy (14,20).

CONCLUSION

Constrictive pericarditis is a rare entity in the spectrum of pericardial diseases. Worldwide, particularly in developing countries, TB is the leading cause in differential diagnosis. The clinical manifestations are primarily non-specific and often bizarre, highlighting the importance of an adequate diagnostic approach to achieve timely diagnoses. The final diagnosis is microbiological or histological. Among the most useful diagnostic tools in daily practice due to their favorable diagnostic performance are imaging studies, such as echocardiogram and cardiac tomography/magnetic resonance imaging, and the analysis of pericardial fluid, even though in many cases, the latter does not allow the diagnosis to be ruled out and biopsies of pericardial tissue may be required. Even rarer are patients with an accumulation of pericardial fluid sufficient to produce cardiac tamponade. In the clinical case, the patient presented with the classic signs of tamponade and obstructive shock that required urgent decompression that saved his life. Forms of pericardial TB with moderate effusion without overt cardiac tamponade are more complex in making the diagnosis. However, TB should always be in the differential diagnosis in places like Colombia, given its high prevalence. Standard six-month antibiotic treatment, the use of steroids, and even pericardiectomy are among the therapeutic pos-

sibilities, which will be individualized according to the characteristics of each patient.

ETHICAL CONSIDERATIONS

As a case report where patient data is included, signed informed consent was requested, and authorization from the Research Ethics Committee of the Hospital Universitario Infantil de San José was required.

ACKNOWLEDGMENT

To the Radiology Service of the Hospital Universitario Infantil de San José.

FINANCING

Self-financed by the authors.

CONFLICT OF INTERESTS

The authors report no conflict of interest.

References

1. Kumar V, Kabbas AC, Aster J. Robbins: patología humana. 10.^a ed. Madrid: Elsevier; 2018.
2. Chiabrando JG, Bonaventura A, Vecchié A, Wohlford GF, Mauro AG, Jordan JH, et al. Management of acute and recurrent pericar-

- ditis: JACC state-of-the-art review. *J Am Coll Cardiol*. 2020 Jan 7;75(1):76-92 <https://doi.org/10.1016/j.jacc.2019.11.021>
3. Wang FF, Hsu J, Jia FW, Lin X, Miao Q, Chen W, Fang LG. Left ventricular strain is associated with acute postoperative refractory hypotension in patients with constrictive pericarditis and preserved ejection fraction. *J Thorac Dis*. 2018 Jul;10(7):4147-55. <https://doi.org/10.21037/jtd.2018.06.124>
 4. Instituto Nacional de Salud. Comportamiento de la vigilancia de tuberculosis, Colombia, 2020. *Bol Epidemiol Sem* [internet]. 2021;11. Disponible en: https://www.ins.gov.co/buscador-eventos/BoletinEpidemiologico/2021_Boletin_epidemiologico_semana_11.pdf
 5. Comas I, Coscolla M, Luo T, Borrell S, Holt KE, Kato-Maeda M, et al. Out-of-Africa migration and Neolithic coexpansion of *Mycobacterium tuberculosis* with modern humans. *Nat Genet*. 2013 Oct;45(10):1176-82. <https://doi.org/10.1038/ng.2744>
 6. Furin J, Cox H, Pai M. Tuberculosis. *Lancet*. 2019;393(10181):1642-56. [https://doi.org/10.1016/S0140-6736\(19\)30308-3](https://doi.org/10.1016/S0140-6736(19)30308-3)
 7. López-López JP, Posada-Martínez EL, Saldarriaga C, Wyss F, Ponte-Negretti CI, Alexander B, et al. Tuberculosis and the heart. *J Am Heart Assoc*. 2021 Apr 6;10(7):e019435. <https://doi.org/10.1161/JAHA.120.019435>
 8. Organización Panamericana de la Salud, Organización Mundial de la Salud. Tuberculosis en las Américas: informe regional 2020. Washington; 2021. <https://doi.org/10.37774/9789275324479>
 9. Ministerio de Salud y Protección Social de Colombia. Informe de evento tuberculosis año 2021: Programa Nacional de Prevención y Control de la Tuberculosis [internet]. Bogotá; 2021 [citado 2022 jul 17]. Disponible en: <https://www.minsalud.gov.co/sites/rid/Lists/BibliotecaDigital/RIDE/VS/PP/ET/comportamiento-tuberculosis-2020.pdf>
 10. Vásquez Y, Ilarraza J, Ruiz N, Benitez M, Moy F. Coinfección tuberculosis y VIH/SIDA, en el Hospital Militar "Dr. Carlos Arévalo". *Bol Venez Infectol* [internet]. 2017 [citado 2022 jul 18];28(1):66-74. Disponible en: <https://pesquisa.bvsalud.org/portal/resource/pt/biblio-878234>
 11. Organización Mundial de la Salud, Organización Panamericana de la Salud. Manual de algoritmos para el diagnóstico de tuberculosis [internet]. 2018. Disponible en: <https://www.paho.org/es/file/52177/download?token=7w-QQnIWL>

12. Amado Garzón S, Moreno Mercado S, Martínez Vernaza S, Lasso JI, Laserna A. Tuberculosis extrapulmonar: un reto clínico vigente. *Univ Méd.* 2020;61(4). <https://doi.org/10.11144/javeriana.umed61-4.reto>
13. Palma RM, Bielsa S, Esquerda A, Martínez-Alonso M, Porcel JM. Eficacia diagnóstica de la adenosina deaminasa en líquido pleural para diagnosticar tuberculosis: metaanálisis de estudios españoles. *Arch Bronconeumol.* 2019;55(1):23-30. <https://doi.org/10.1016/j.arbres.2018.05.007>
14. Cantres-Fonseca OJ, Rodríguez-Cintrón W, Del Olmo-Arroyo F, Báez-Corujo S. Extra pulmonary tuberculosis: an overview. En: Singh Chauha N, editor. *Role of microbes in human health and diseases.* IntechOpen; 2019. <http://dx.doi.org/10.5772/intechopen.81322>
15. Lagoeiro Jorge AJ, De Andrade Martins W, Batista da Costa WL, Kiyomura Rossli A, Chaves Ferreira Coelho L, Shinji Nobre Soussume W. Pericarditis constrictiva por tuberculosis, una condición de difícil diagnóstico. *Insuf Card* [internet]. 2018;13(2):97-100. Disponible en: http://www.scielo.org.ar/scielo.php?script=sci_arttext&pid=S1852-38622018000200008&lng=es
16. Esquivel SL, Fleites GY, González RY. Utilidad de los medios imagenológicos en la pericarditis tuberculosa. *CorSalud.* 2021;13(1):86-92.
17. Horacio Casabé J. Consensus statement of pericardial diseases/abridged version Argentine Society of Cardiology. *Rev Arg Cardiol* [internet]. 2017;85(3):268-85. Disponible en: <https://dialnet.unirioja.es/servlet/articulo?codigo=6190143>
18. Sharma NK, Waymack JR. Acute cardiac tamponade. En: *StatPearls* [internet]. Treasure Island (FL): StatPearls Publishing; 2023. Disponible en: <https://pubmed.ncbi.nlm.nih.gov/30521227/>
19. Navarro-Ulloa OD, Bello-Espinosa A, Borré-Naranjo D, Ramírez Barranco R, Sarmiento Agámez O, Arteta-Acosta C. Derrame pericárdico y taponamiento cardíaco. *Rev Colomb Cardiol.* 2017;24(6):622.e1-622.e5. <https://doi.org/10.1016/j.rccar.2017.04.009>
20. Consenso enfermedades del pericardio [internet]. *Rev Arg Cardiol* [internet]. 2017 [citado 2022 sep 5];85(supl. 7). Disponible en: <https://www.sac.org.ar/wp-content/uploads/2018/08/consenso-de-pericardio-2018.pdf>



Esta obra está bajo una licencia de Creative Commons Reconocimiento-NoComercial 4.0 Internacional